



# Unusual Thrombosis

Sergio Siragusa

*PRO.MI.SE*

*(Dipartimento Biomedico di Medicina Interna e Specialistiche)*

*Università degli Studi di Palermo*

---



## DICHIARAZIONE CONFLITTI D'INTERESSI

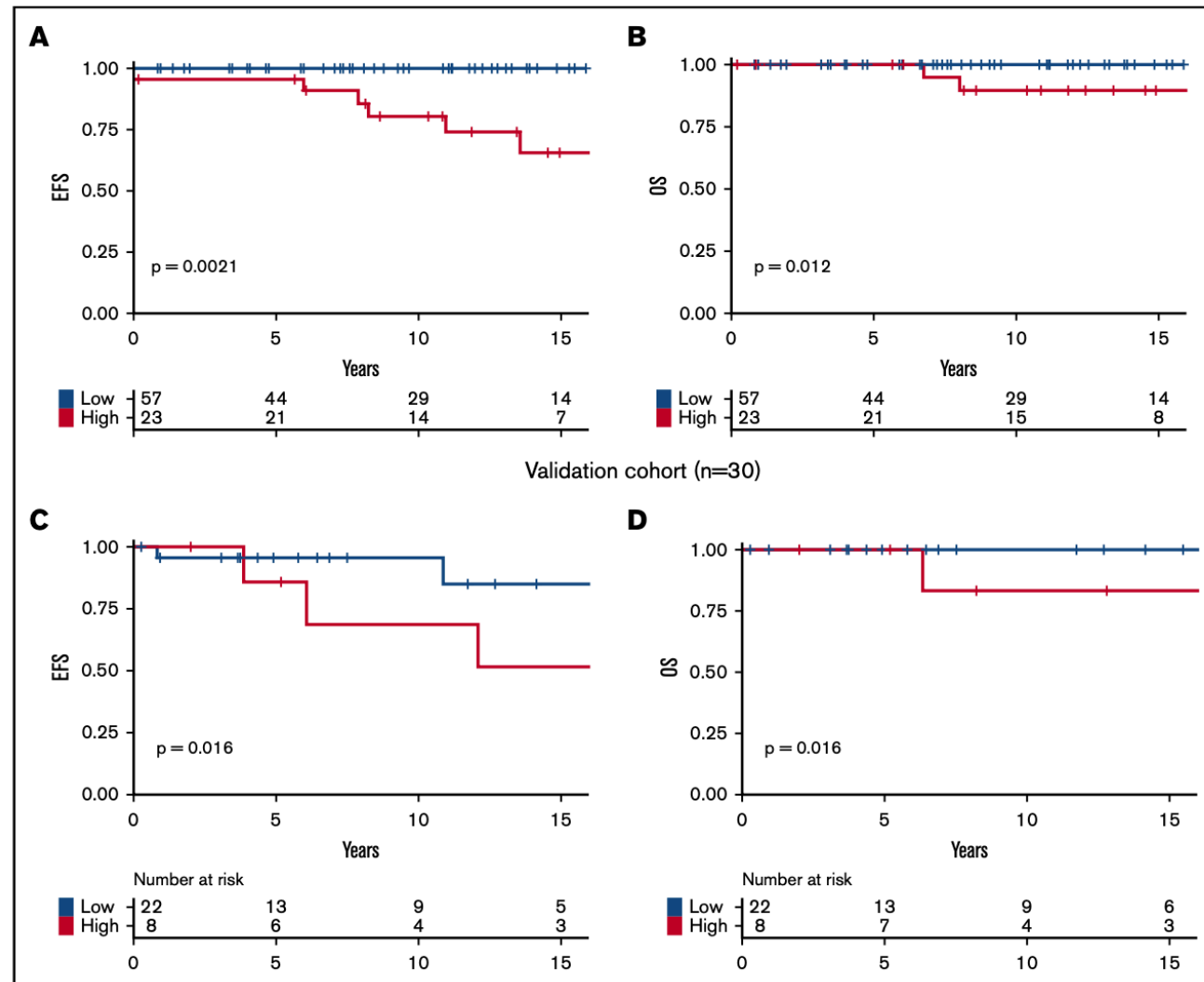
Sergio SIRAGUSA

Come da nuova regolamentazione della Commissione Nazionale per la Formazione Continua del Ministero della Salute, è richiesta la trasparenza delle fonti di finanziamento e dei rapporti con soggetti portatori di interessi commerciali in campo sanitario.

- Posizione di dipendente in aziende con interessi commerciali in campo sanitario **(NIENTE DA DICHIARARE)**
- Consulenza ad aziende con interessi commerciali in campo sanitario **(NOVONORDISK, CSL, ROCHE, BAYER, Takeda, Novartis, Amgen)**
- Fondi per la ricerca da aziende con interessi commerciali in campo sanitario **(ROCHE, PFEIZER)**
- Partecipazione ad Advisory Board **(AMGEN, BAYER, NOVARTIS, NOVONORDISK, CSL, Uniqure, Takeda, SOBI)**
- Titolarità di brevetti in compartecipazione ad aziende con interessi commerciali in campo sanitario **(NIENTE DA DICHIARARE)**
- Partecipazioni azionarie in aziende con interessi commerciali in campo sanitario **(NIENTE DA DICHIARARE)**
- Altro



# OS & EVF accordingly to risk factor for thrombosis in MNP population



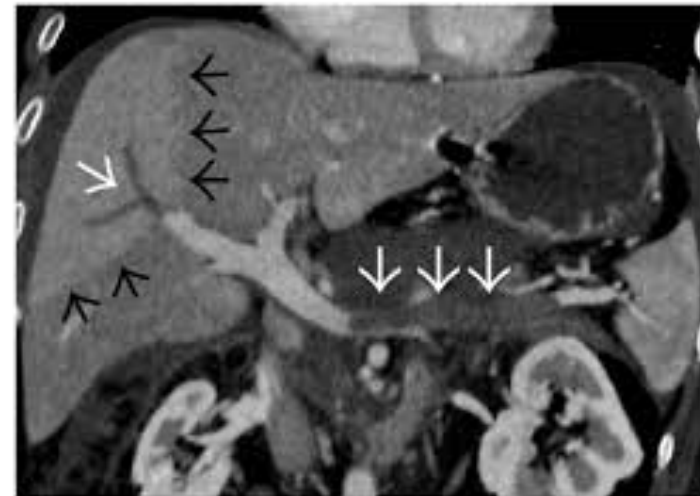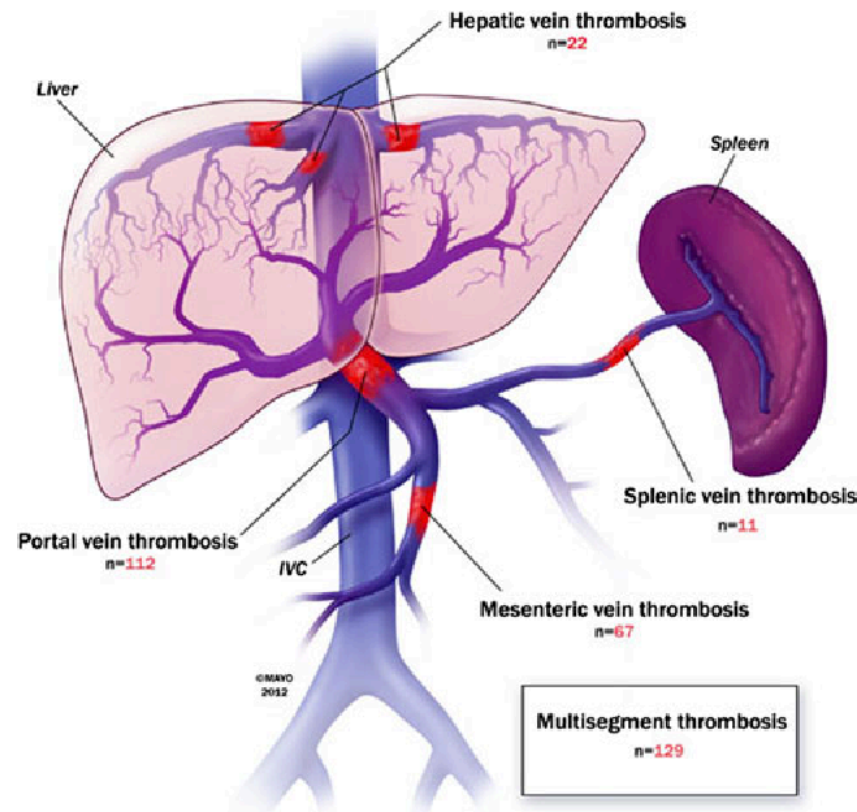


- 1. What do you mean for unusual vein thromboEmbolism (un-VTE)?**
  - 2. Why such thrombosis appears more frequently in MNPs?**
  - 3. How we can diagnose and treat un-VTE?**
  - 4. Un-VTE: in MNPs only?**
-

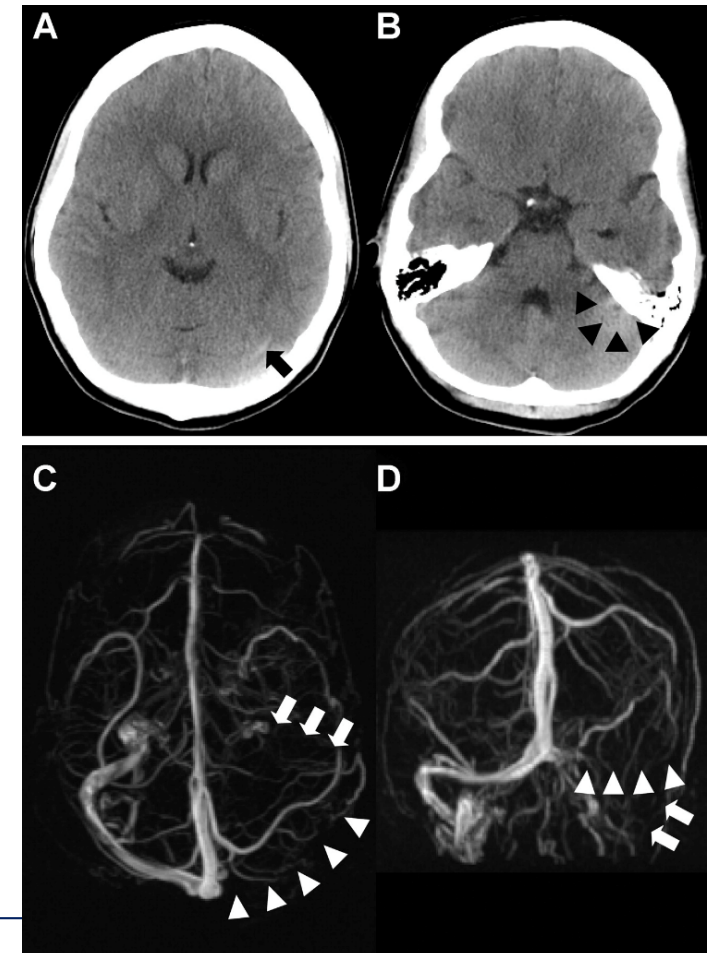
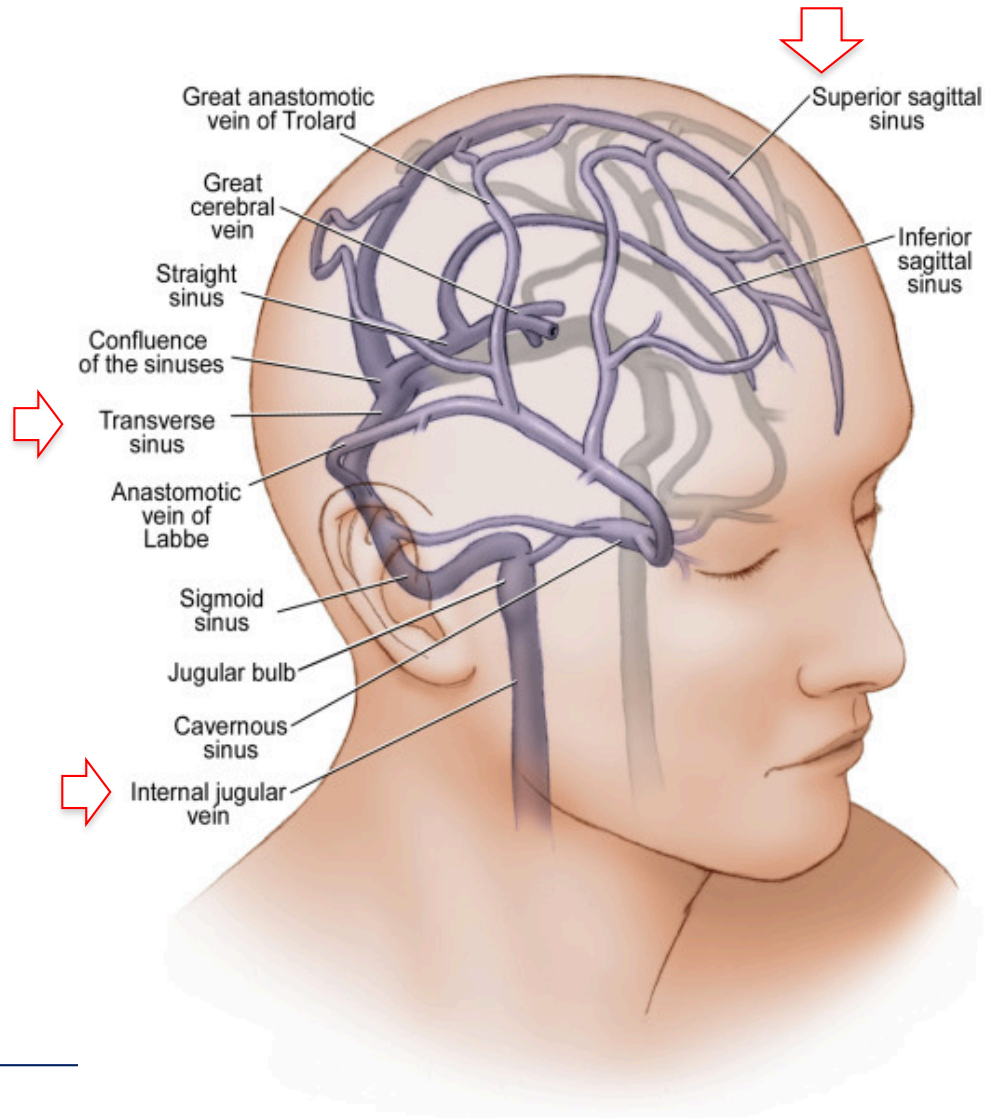


- 1. What do you mean for unusual vein thromboEmbolism (un-VTE)?**
  2. Why such thrombosis appears more frequently in MNPs?
  3. How we can diagnose and treat un-VTE?
  4. Un-VTE: in MNPs only?
-

# Splancnic Vein Thrombosis (SVT)

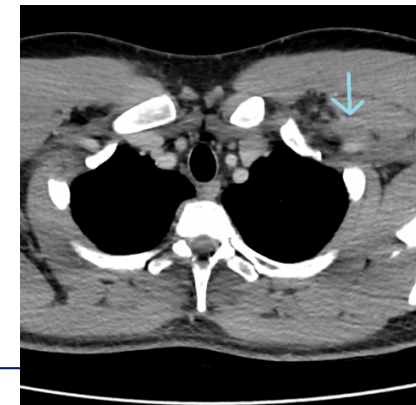
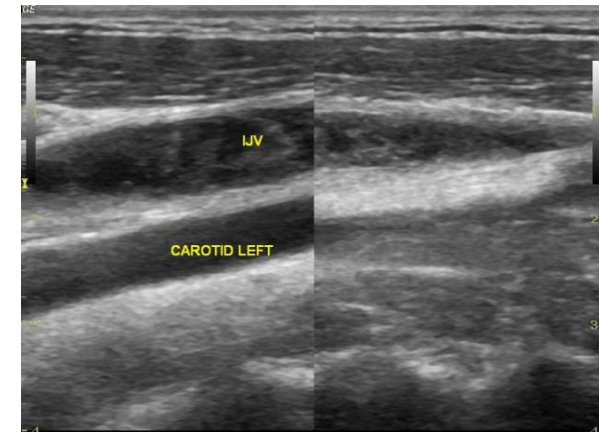
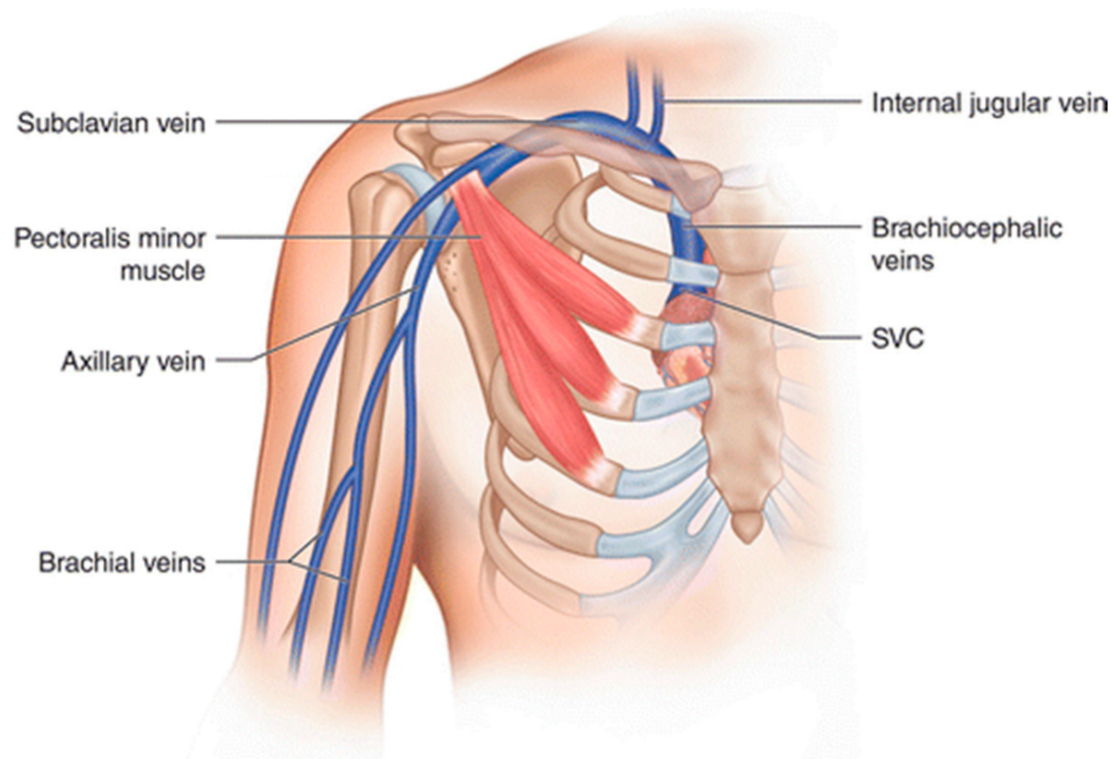


# Cerebral Vein Thrombosis (CVT)





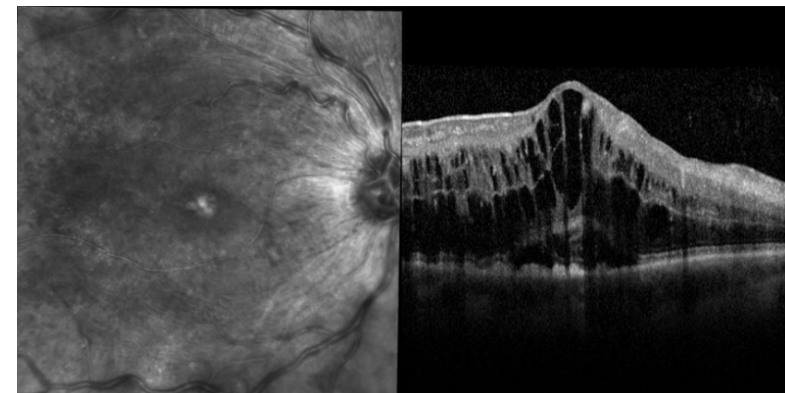
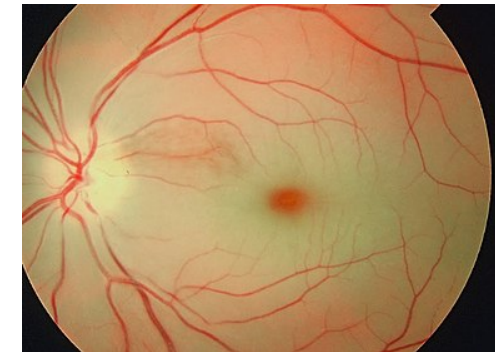
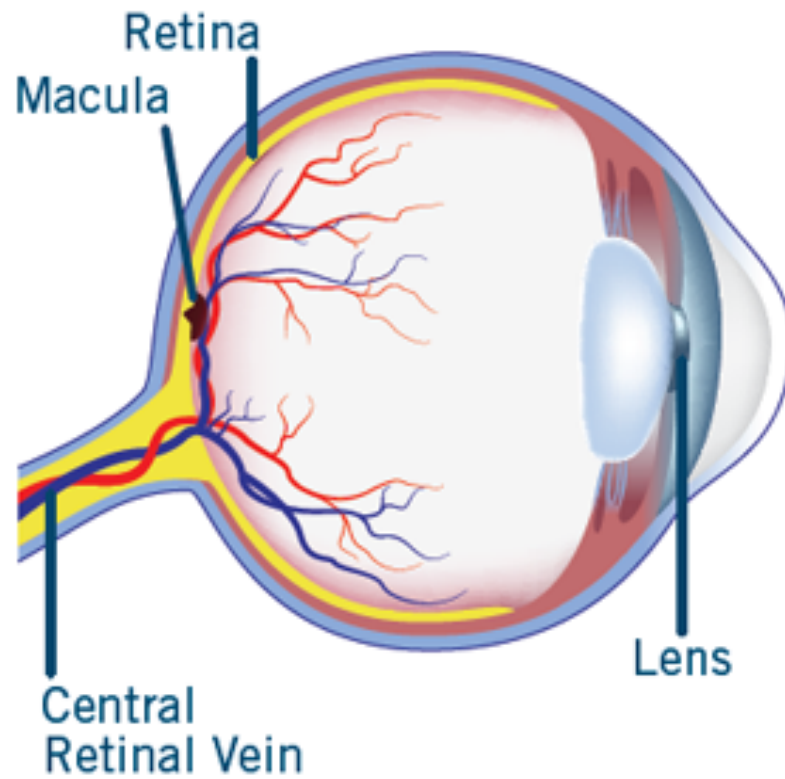
# Upper Extermity Vein Thrombosis (UE-VT)





# Central Retinal Vein Thrombosis (c-RVT)

## Healthy Eye





1. What do you mean for unusual vein thromboEmbolism (un-VTE)?
  - 2. Why such thrombosis appears more frequently in MNPs?**
  3. How we can diagnose and treat un-VTE?
  4. Un-VTE: in MNPs only?
-



# Expected Incidence of un-VTE in general and MNPs patients

Expected Incidence (EI) in general population:  
1/1.000.000 pop

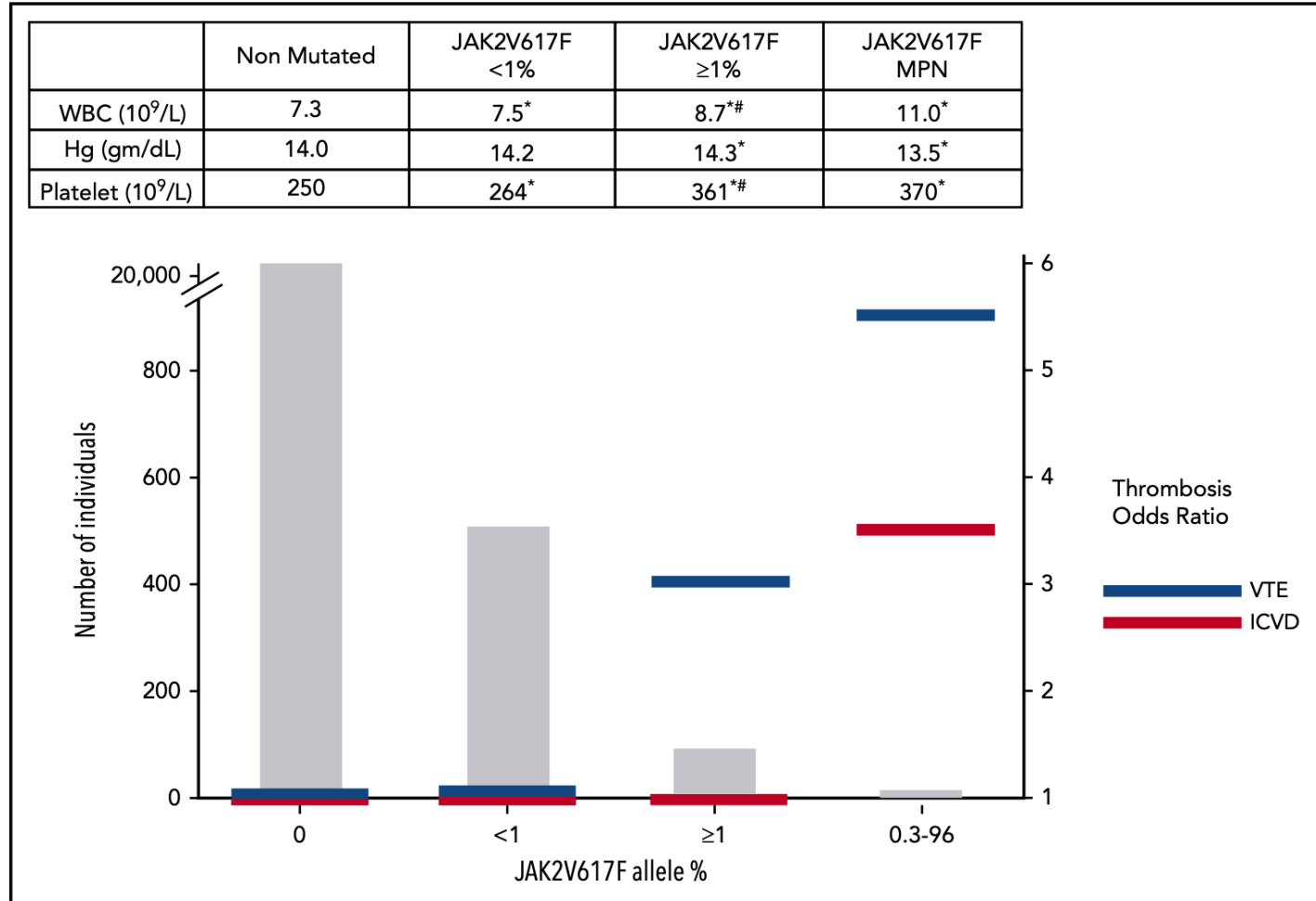
EI in MNPs patients:  
1/100; 1/1.000 pts

---



# Prevalence, relative thrombosis risk, and average blood counts stratified by JAK2V617F VAF

Mean blood counts of 19.313 patients with JAK2V617F2 (nonmutated), 508 patients with JAK2V617F1 (< 1% VAF) non-MPN, 105 patients with JAK2V617F1 (>1% VAF) non-MPN, and 16 patients with MPN (14 of whom were JAK2V617F1 with VAF 0.3% to 96%) (upper panel).

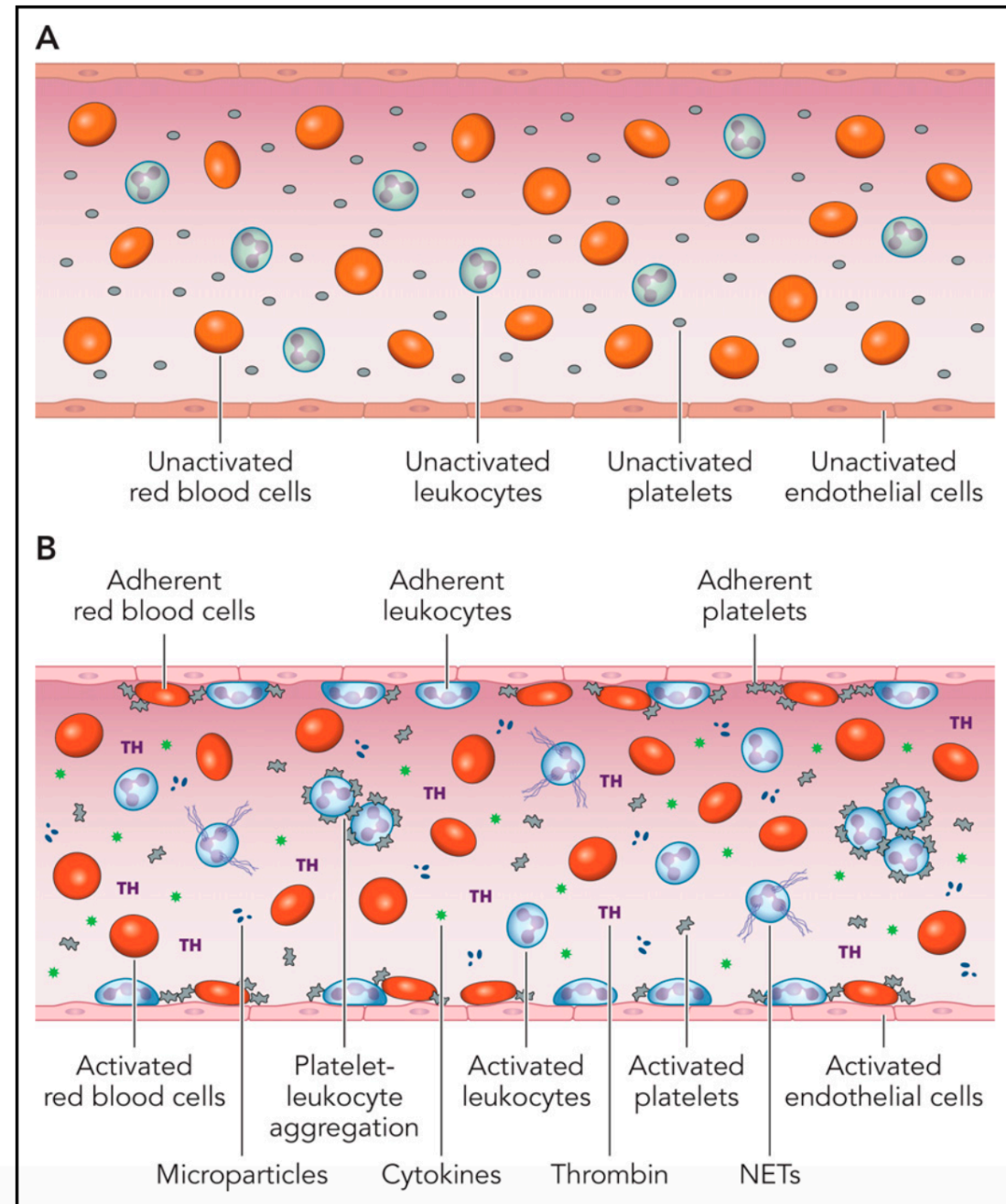


\*Significantly different compared with nonmutated;  
#significantly different compared with JAK2V617F1 ,1% VAF.

## The prothrombotic and proadhesive blood milieu in the MPN

Activation or dysfunction of ECs in the MPNs changes this milieu.

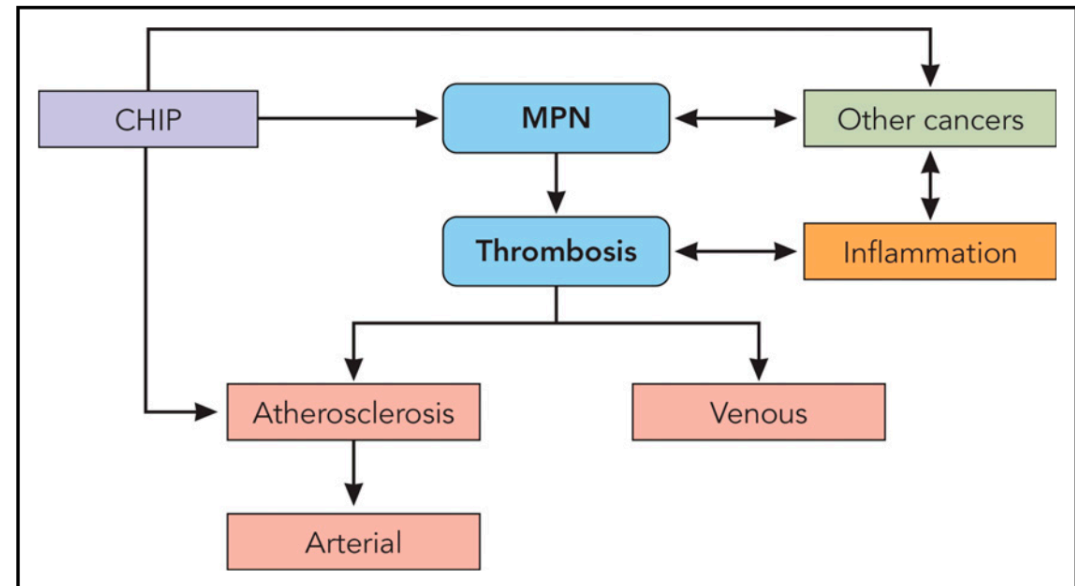
The main triggers for this “thromboinflammatory” state are most likely (i) cell-intrinsic abnormalities of platelets, leukocytes, red cells, and ECs as a function of their origin in a mutant hematopoietic clone and (ii) the establishment of a proinflammatory state, both serving as mutually amplifying factors.



# The pathogenesis of thrombosis in the MPNs

**MPNs and the CHIP from which they originate are both risk factors for venous thrombosis and atherosclerosis.** Atherosclerosis, in turn, is the major substrate for arterial thrombosis.

MPNs and systemic inflammation promote each other bidirectionally. Systemic inflammation itself, independent of MPNs, provokes venous thrombosis, atherosclerosis, and arterial thrombosis.





1. What do you mean for unusual vein thromboEmbolism (un-VTE)?
  2. Why such thrombosis appears more frequently in MNPs?
  - 3. How we can diagnose and treat un-VTE?**
  4. Un-VTE: in MNPs only?
-



# Diagnosis of un-VTE (& clinical suspicion)

Clinical suspicion:

**SVT:** abdominal pain, discomfort (not always unique in patients with splenomegaly) - **D:** -> **angio-CT/RMN**

**CVT:** confusion, seizure, headache, almost never emiparesis – **D:** -> **angio-RMN, no CT scan**

**UE-VT:** swelling of a single arm, pain – **D** -> **UE-CUS**

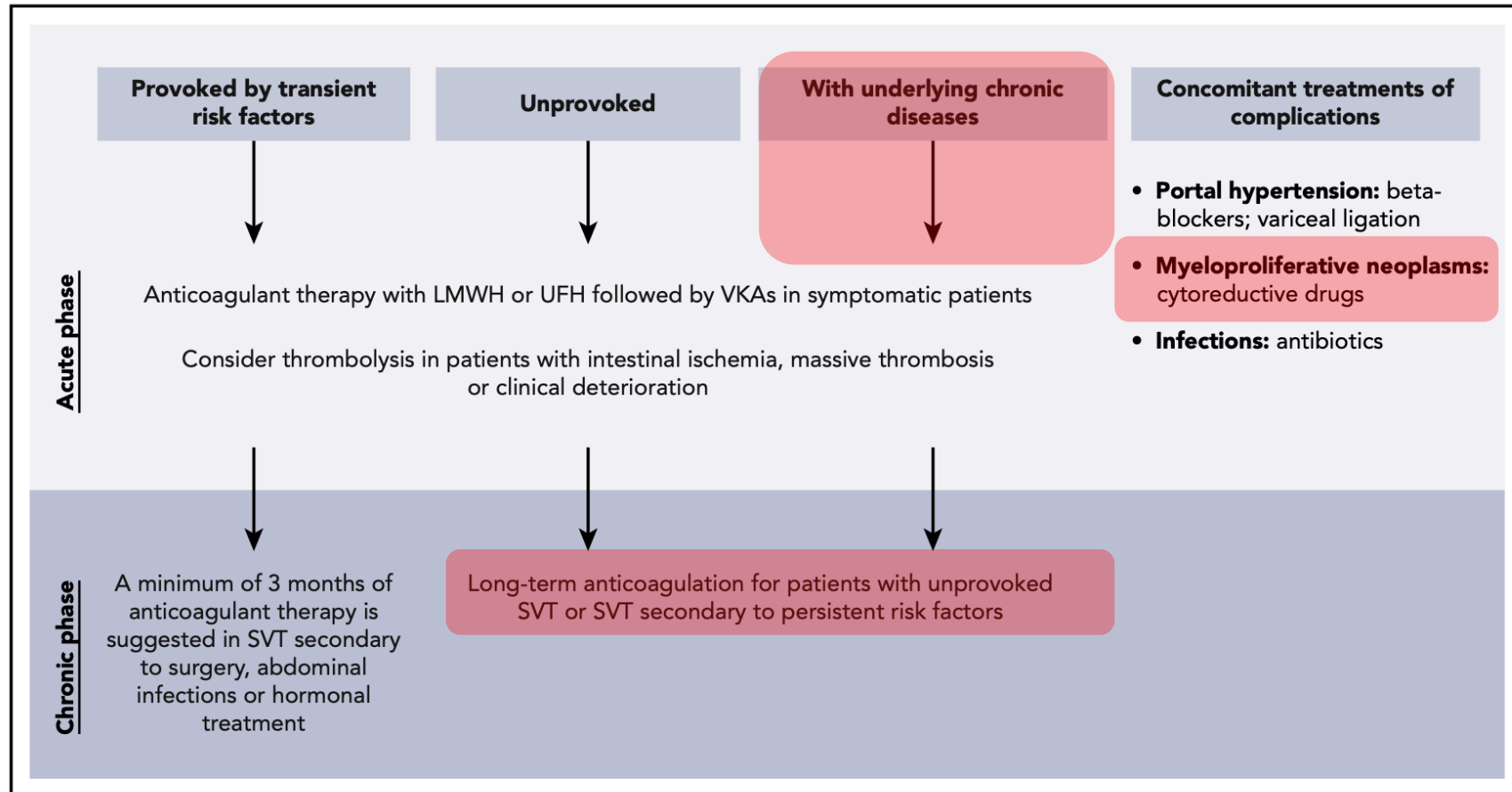
**C-RVT:** sudden loss of vision, diplopia – **D:** **flurography**

---



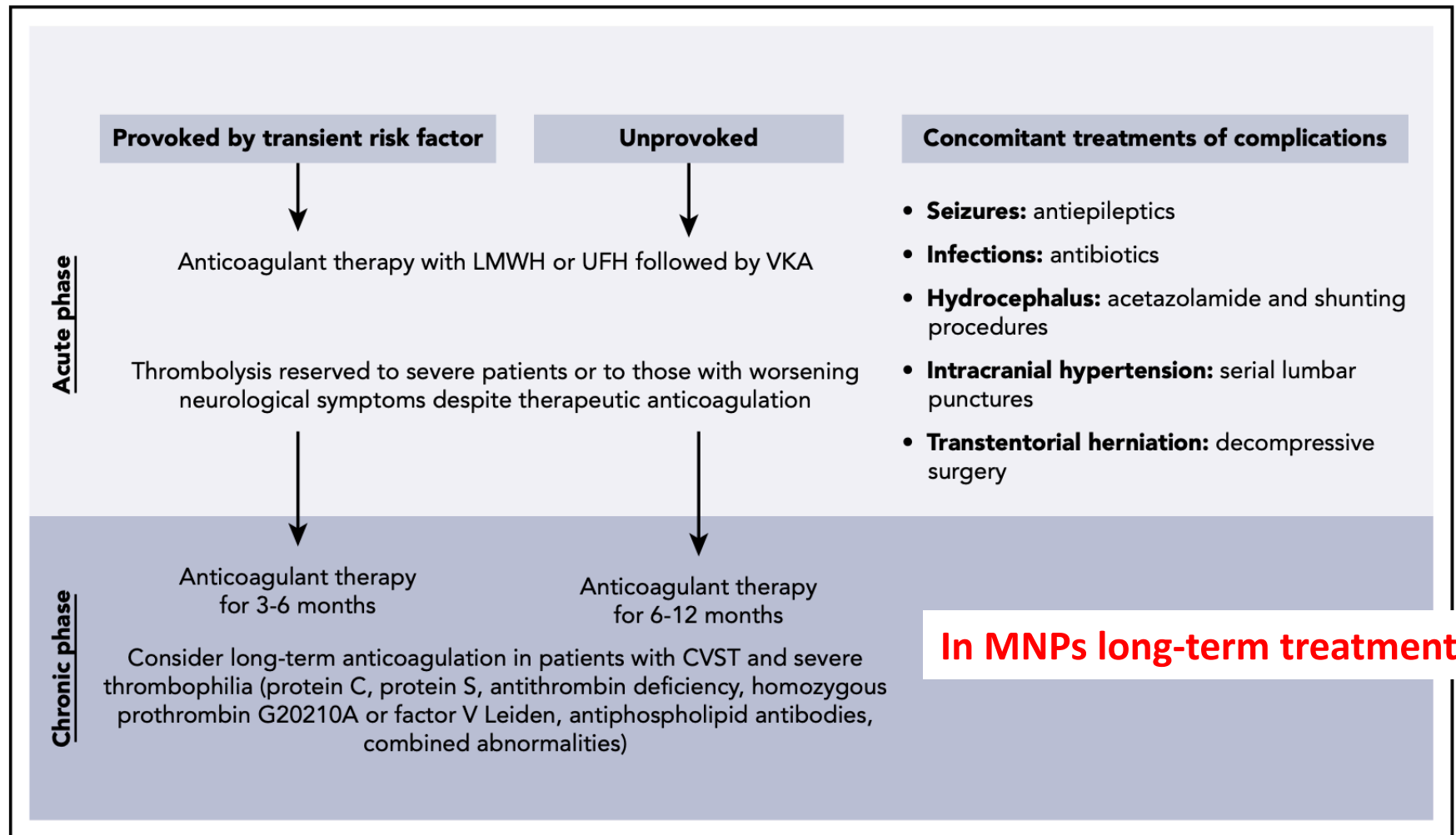


# Recommendations for treatment of SVT



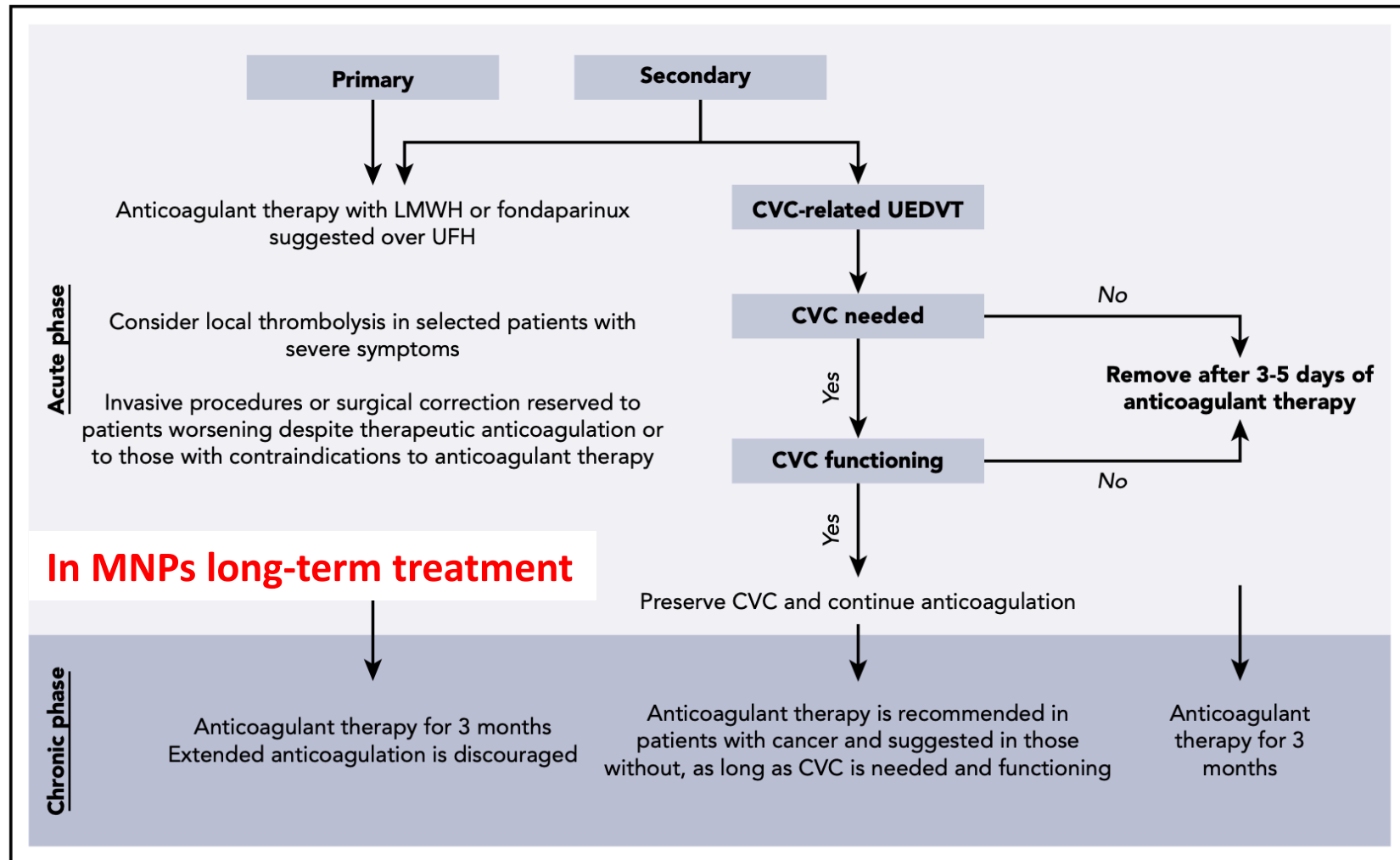


# Recommendations for treatment of CVT





# Recommendations for treatment of UE-VT





# Ongoing trials on DOACs in un-VTE

Title	Study type	Intervention	Main outcome	No. of patients	Start date	Recruitment status
A Clinical Trial Comparing Efficacy and Safety of Dabigatran Etexilate With Warfarin in Patients With Cerebral Venous and Dural Sinus Thrombosis (RE-SPECT CVT) (NCT02913326)	Interventional (phase 3), randomized, parallel assignment, open label	Dabigatran etexilate vs warfarin for 6 mo	Composite rate of major bleeding and venous thromboembolism	120	13 Dec 2016	Completed
The Efficacy and Safety of Dabigatran Etexilate for the Treatment of Cerebral Venous Thrombosis (NCT03217448)	Interventional (phase 3), randomized, parallel assignment, open label, single blind (outcomes assessor)	Dabigatran etexilate vs warfarin for 6 mo	Recanalization after 6 mo	80	30 Oct 2017	Recruiting
Comparison of the Efficacy of Rivaroxaban to Coumadin (Warfarin) in Cerebral Venous Thrombosis (NCT03191305)	Interventional, nonrandomized, parallel assignment, single blind (participants)	Rivaroxaban vs warfarin	Hemorrhage or recurrent CVT based on repeated MRI at 6 mo	50	—	Not yet recruiting
Study of Rivaroxaban for CeREbral Venous Thrombosis (SECRET) (NCT03178864)	Interventional (phase 2), randomized, parallel assignment, open label, single blind (outcomes assessor)	Rivaroxaban vs standard of care	Composite rate of all-cause mortality, symptomatic intracranial bleeding, and major extracranial bleeding at 6 mo	380	12 Mar 2019	Recruiting
Comparing Treatment Outcomes in CVT Patients Who Were Treated With Warfarin and Rivaroxaban in Isfahan, Iran (NCT03747081)	Interventional (phase 1/2), randomized, parallel assignment, open label	Rivaroxaban vs warfarin for 3 mo	Modified Rankin scale at 3 mo	50	1 Sep 2018	Recruiting



1. What do you mean for unusual vein thromboEmbolism (un-VTE)?
  2. Why such thrombosis appears more frequently in MNPs?
  3. How we can diagnose and treat un-VTE?
  - 4. Un-VTE: in MNPs only?**
-

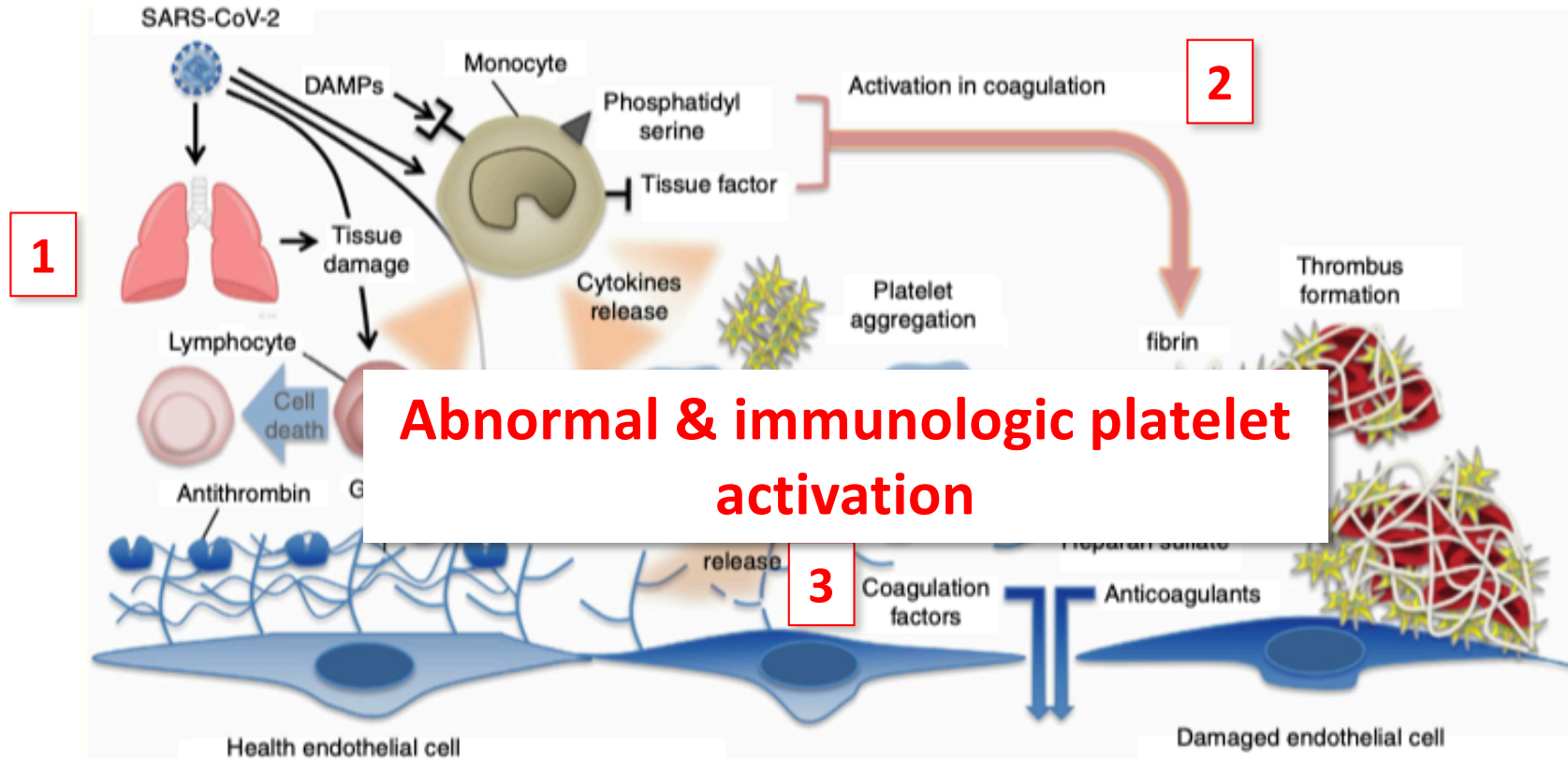


# Vaccine-Induced Immune Thrombotic Thrombocytopenia

Vaccination with ChAdOx1 nCov-19 can result in the rare development of immune thrombotic thrombocytopenia mediated by platelet-activating antibodies against PF4, which clinically mimics autoimmune heparin-induced thrombocytopenia (but is NOT HIT!)

---

# Mechanisms of coagulation activation in Covid-19 & VITT



COVID-19 and damage-associated molecular patterns (DAMPs) activate monocytes. Activated monocytes release inflammatory cytokines and chemokines that stimulate neutrophils, lymphocytes, platelets, and vascular endothelial cells. Monocytes and other cells express tissue factor and phosphatidylserine on their surfaces and initiate coagulation



## Conclusions on un-VTE

Unusual VTE is more common in MNPs than in general population

Mechanism are certainly related to a «pro-inflammatory status» (Thromboinflammation)

Monoclonal myeloid precursors play an important role

Treatment should be based on long-term anticoagulation (warfarin and DOACs, but wait for an official status)

---